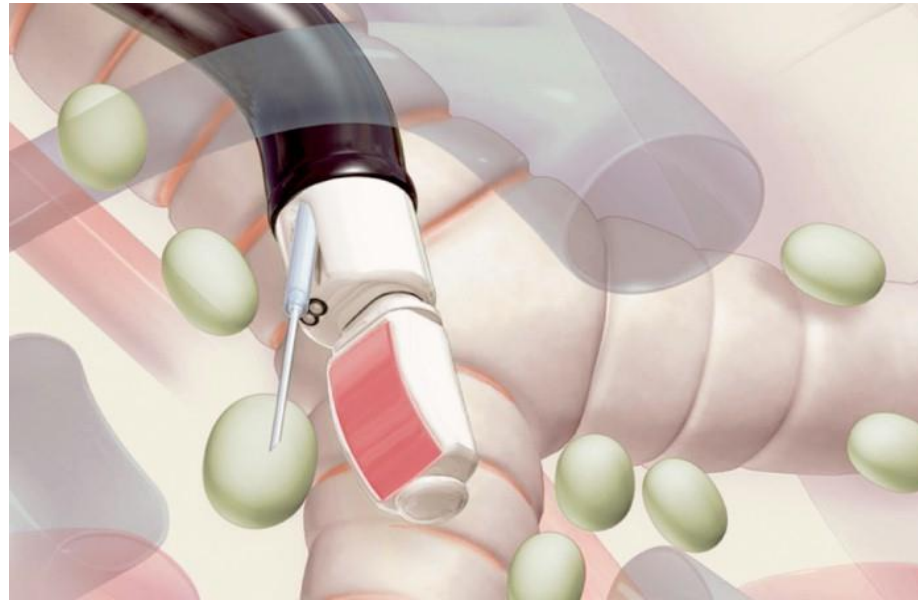

Endobronchial Ultrasound

Nuha Abdellatif

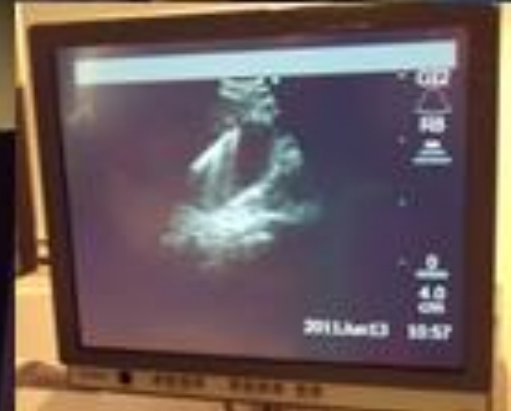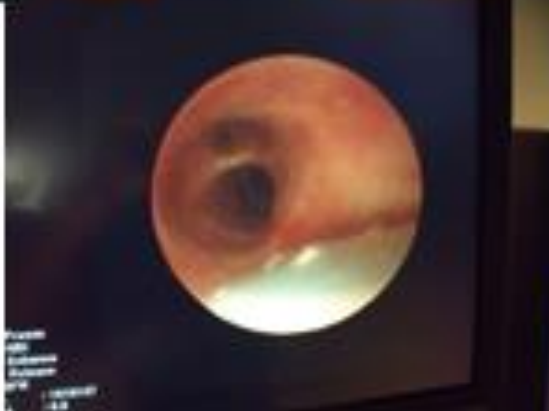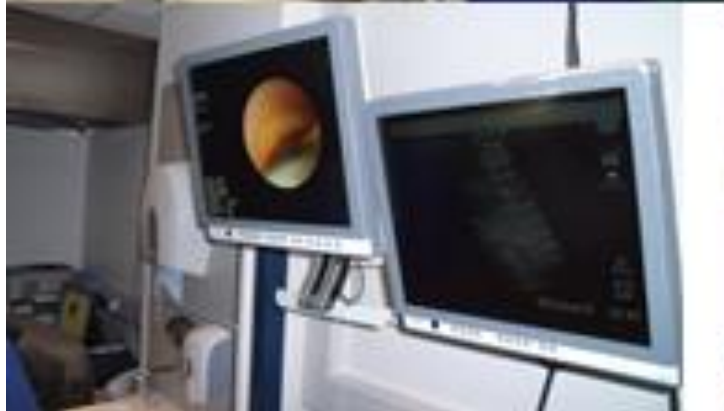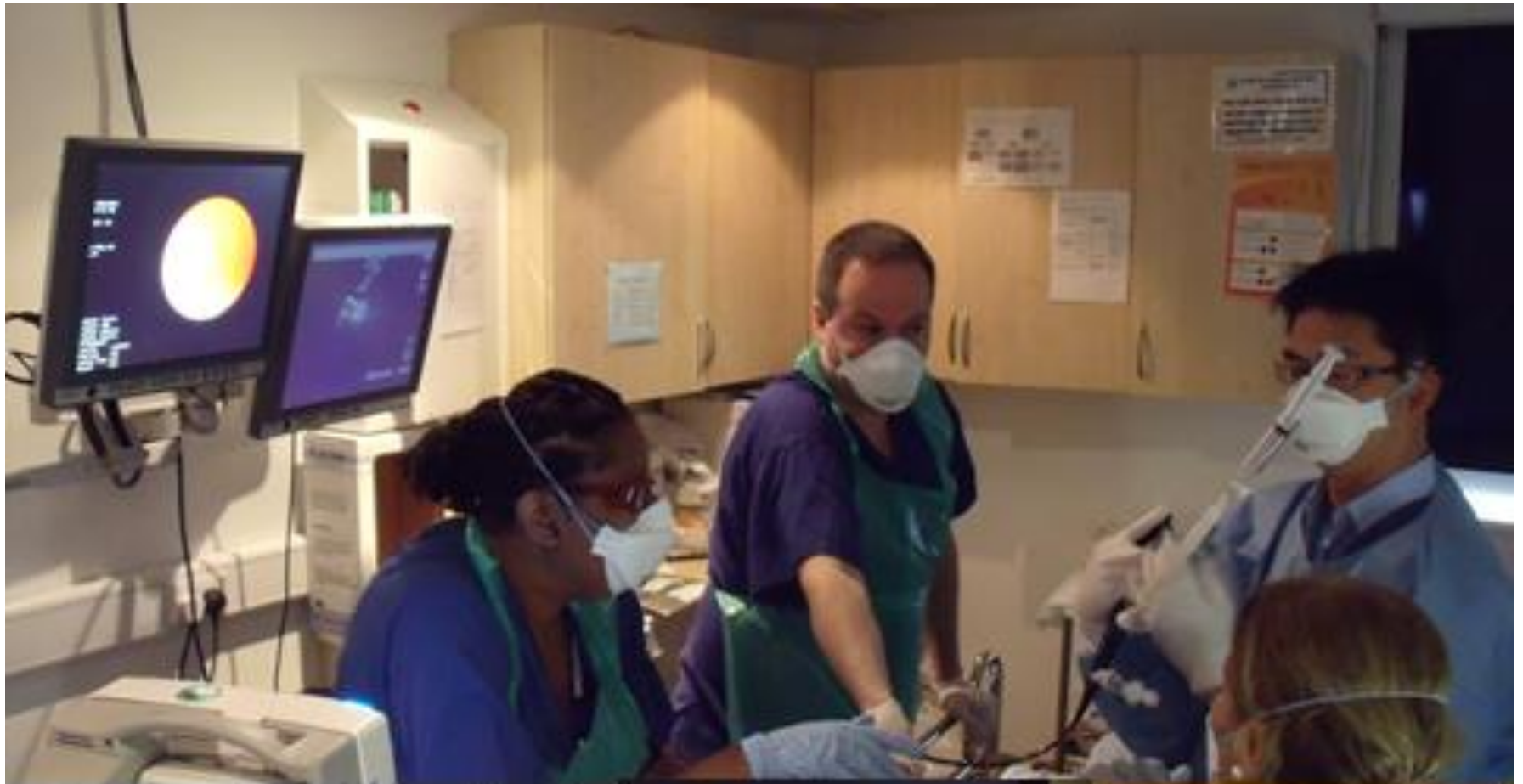Senior Biomedical Scientist

St Mary's Hospital

Imperial College Healthcare NHS Trust

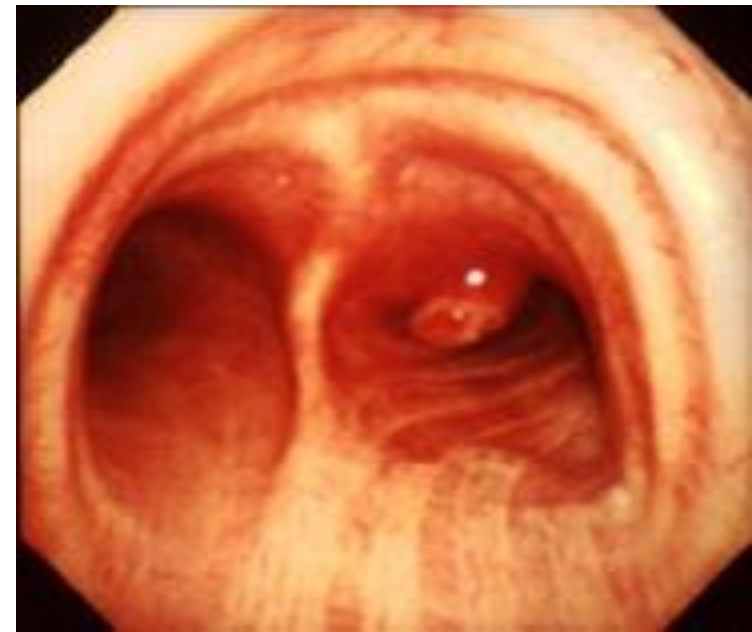
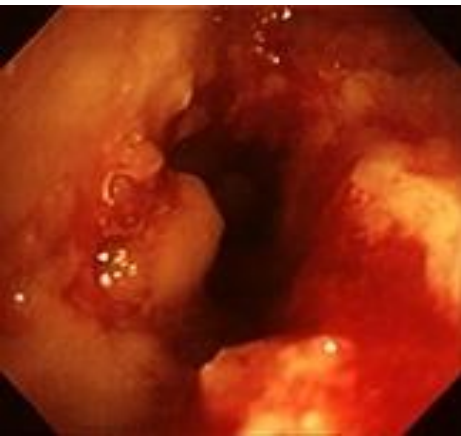


Imperial College Healthcare **NHS**
NHS Trust



Expanding beyond the airway

- Airway lesions visible by conventional bronchoscopy
- Mediastinal node sampling
- Peri-bronchial lesions not visible



EBUS applications

- Primary diagnosis malignancy
- Rules out other diagnoses
- Staging malignancy
- Post adjuvant therapy staging
- Peri-airway sampling of masses
- Differentiate a new primary from recurrence of previously treated lung cancer
- Fiducial placement
- TB/ sarcoidosis

Benefits of Ebus

Provides real-time imaging of the surface of the airways, blood vessels, lungs, and lymph nodes

Allows access to difficult-to-reach areas and accesses small lymph nodes

Rapid onsite pathologic evaluation Pathologists/ Biomedical Scientists in the operating room can process and examine samples as they are obtained and can request additional samples to be taken immediately if needed

EBUS is performed under moderate sedation or general anaesthesia

Patients recover quickly and can usually go home the same day as minimally invasive procedure

Advantage of Biomedical Scientists attending EBUS

- Extremely Rapid as Biomedical Scientists onsite
- Cost Effective Ebus training for Biomedical Scientists available in house
- Implementation of HPV Primary Screening in 2020 for Cervical Cytology will result in more Biomedical Scientists available to attend EBUS

Imperial College NHS Trust

Cytology Workload 2017

- Cervical Cytology in 2017 56,729 (decreased more than 10% from 2016)
- Diagnostic Cytology 10,500 of which 30% FNA (increases 5%year)
- FNA EBUS clinic managed by cyto pathologist has now been terminated
- In 2017 23 Consultants attended the EBUS Clinic
- 121 Biomedical Scientists attended in 2017

BMS Training Course in CT/US guided FNA Cytology Imperial College NHS Trust Dept. of Cellular Pathology

- **Aim of the course:**
- to train senior cytology BMSs in the provision of assistance to radiologists and clinicians in the evaluation of cytological material obtained through CT/US guided FNAs including EUS and EBUS procedures
- to maximize the potential of cytological material for diagnostic ancillary techniques and research protocols

The course was ran in 3 hour sessions once a week in 2015 from 10.00 to 13.00 on a weekly basis including lectures by BMSs, cytopathologists, radiologists and clinicians

March 11, 9 am- Cytology of respiratory tract

Dr Onn Kon - Indications and Clinical setting

Dr C Wright - EBUS

March 18, 10 am - Cytology of respiratory tract

Dr F Mauri – Lung Pathology

Dr F Mauri - Cytology and ancillary techniques

March 26, 14.00 – 14.45 Lung and Thyroid

Dr N Strickland - CT guided FNA

Dr R Dina – Thyroid Cytology and ancillary techniques

April 1, 10 am - FNA of Thyroid

Mr F Palazzo - Clinical setting

Dr M Crofton - - US guided FNA of thyroid nodules

April 8, 10 am - FNA of pancreas and cytology of biliary tract

Dr P Vlavianos - Clinical setting

Dr R Dina - Cytology and ancillary techniques

April 15, 10 am – FNA of head and neck

Dr A Sandison - Clinical setting and Pathology

Dr D Blunt - US guided FNA of head and neck

Dr R Dina – Head and neck cytology

May – Assessment and Evaluation

Ebus/ FNA update Course started Wednesday 12th October 2016

Lecture 1

12th October 2016, EBUS/ EUS in Imperial North West London Pathology Update

Lecture 2

19^h October 2016 Head and Neck Cytopathology with special emphasis on salivary gland tumours

Lecture 3

26th October 2016 Multi header Microscopy Session – Parotid Swelling

Lecture 4 Cytology Head and Neck Virtual Multi header Test

2nd November 2016

Lecture 5 Respiratory Tract presented by Dr Nandita Gupta

9th November 2016

Lecture 6 Techniques in Respiratory Cytology (Sptum, BAL, EBUS)

16th November 2016

Lecture 7 Lymph Nodes and Multiheader Microscopy Session

9th November 2017

Lecture 8 Thyroid and Multiheader Session Microscopy Session

22nd February 2017

Advantages of in room CYTOLOGY

- cellularity of sample assessed
 - adequacy for subsequent full laboratory analysis
- allows FNA to be repeated if sample inadequate
- spares patient repeated sampling if adequate
- relatively high sensitivity and specificity for malignancy
 - provides a preliminary diagnosis in most cases – 74%
 - accurate in comparison to the final
 - Allows decision to be sent to flow cytometry to be made promptly
 - Reduces waste in resources
- FNA accurate when compared with cytopathology report – 86% cases

Current setting

- All U/S-guided FNAs at HH if ROSE requested are attended by a BMS Grd7/8
- All U/S-guided FNAs at SMH smeared by the BMS
- EBUS-guided FNAs attended by a BMS if granulomas suspected (TB or sarcoid), and for cancer suspicion/staging for adequacy.

NICE 2011 (CG121)

Diagnosis and staging

- Choose investigations that give the most information about diagnosis and staging with the least risk to the patient. Think carefully before performing a test that gives only diagnostic pathology when information on staging is also needed to guide treatment.
- Offer PET-CT, or EBUS-guided TBNA, or EUS-guided FNA, or non-ultrasound-guided TBNA as the first test for patients with an **intermediate probability of mediastinal malignancy** (lymph nodes between 10 and 20 mm maximum short axis on CT) who are potentially suitable for treatment with curative intent.

Gene Xpert™ in EBUS

- PCR Sensitivity for culture proven MTB – 72.6%
 - Cytology sensitivity – 92%
 - Dual 96.6%
- All smear positive cases were PCR positive
- Average time culture to positivity of 13 days
- The PCR +ve samples had a significantly lower median time to positivity of 14 days compared to 17 days for those that were PCR negative
- Granulomatous reactions with caseation (Cytology Grade 1) were seen significantly more frequently in the PCR positive group
- 7 culture-negative were PCR positive
 - all patients had clinical disease compatible with active tuberculosis
 - including two patients with HIV
- 2 cases were correctly identified as Rifampicin-resistant by the Xpert® test
- One case of multi-drug-resistant TB was not detected as rifampicin-resistant by the Xpert® test despite further investigations revealing that the detected mutations were in the 81 bp core region of the *rpoB* gene which Xpert® assesses

Service Provision

- 4 bronchoscopy morning lists per week
- Dr Kon/ Dr Wickremasinghe/ Dr Berry
- E-mail referrals/ Fax/ Phone
 - Contact number
 - IEP imaging
 - PET images
 - FBC/clotting
- E-mail immediate results
- Positive cultures/sensitivities forwarded
- New Endoscopy Unit 2014 – dedicated bronchoscopy room

EBUS issues

- Higher sedation levels – 2 bronchoscopists optimal
- FBC/clotting pre
- Specific equipment
- Training curve
- Dedicated expertise
- Rapid on site cytology
 - Shorter procedure time
 - Optimise sample handling
 - EGFR/ALK mutation analysis
 - TB culture
- Culture as ‘tissue’ for 12 weeks

Summary

- EBUS useful in granulomatous disease AND in ensuring target is being reached when abnormalities is suspected
- High sensitivity in TB and sarcoidosis
- Non-caseating granuloma not exclusive to sarcoidosis
- PCR
 - rapid and as good as smear
 - Does not replace culture
- Using 3 mode testing (cytology/micro-PCR/IGRA) gives excellent sensitivity in TB
- Lymphoma issues, flow cytometry invaluable

Slides

CASE 1 MN18-251

Collection of epithelial macrophages and histiocytes. Some are dispersed.

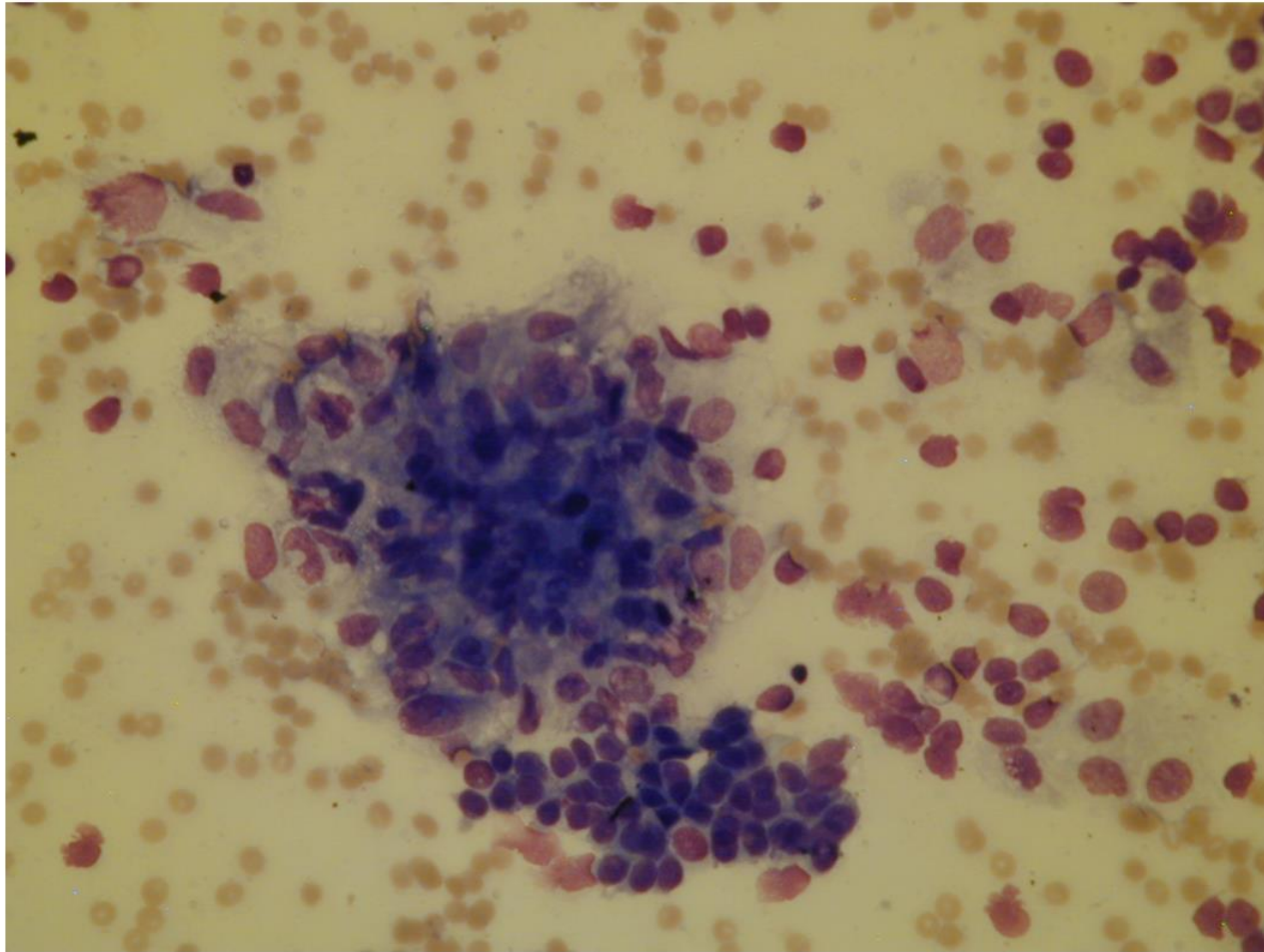
No necrosis.

Second pass has many lymphoid cells

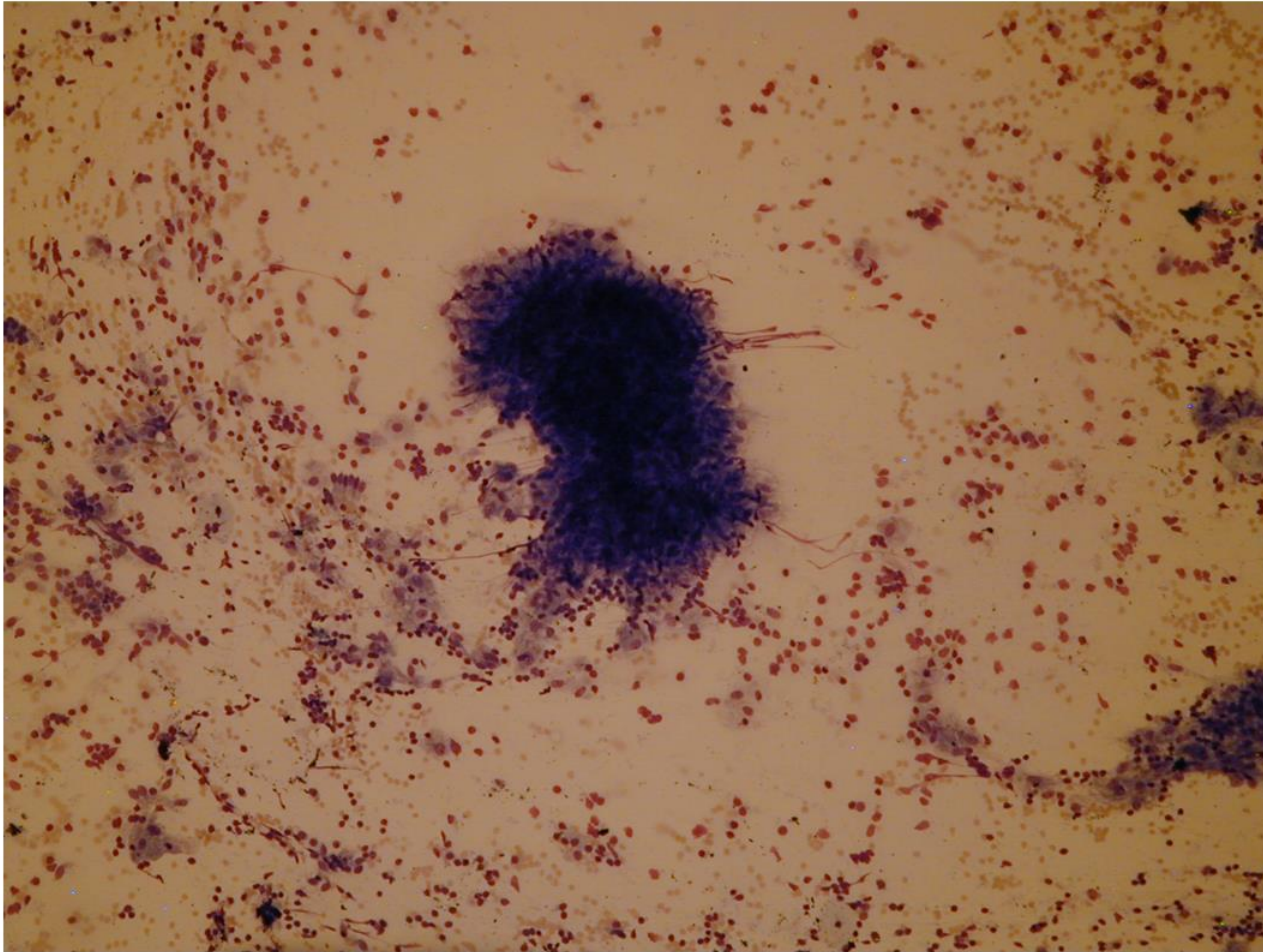
PAP slide does not mimic the MGG slides

Granuloma present in clot

SLIDE 1 MN18-251



SLIDE 1 MN18-251

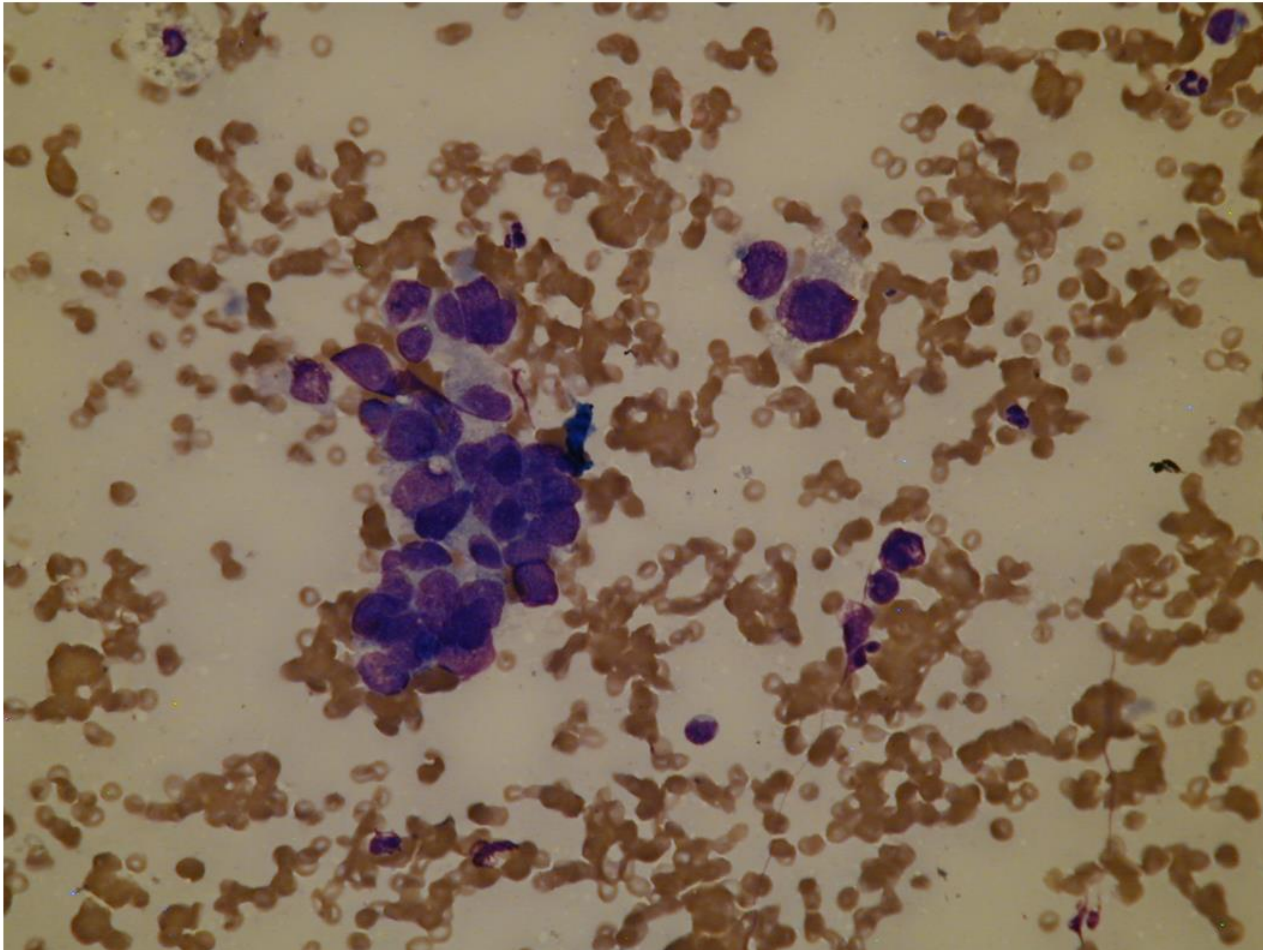


Case 2 CN17-344

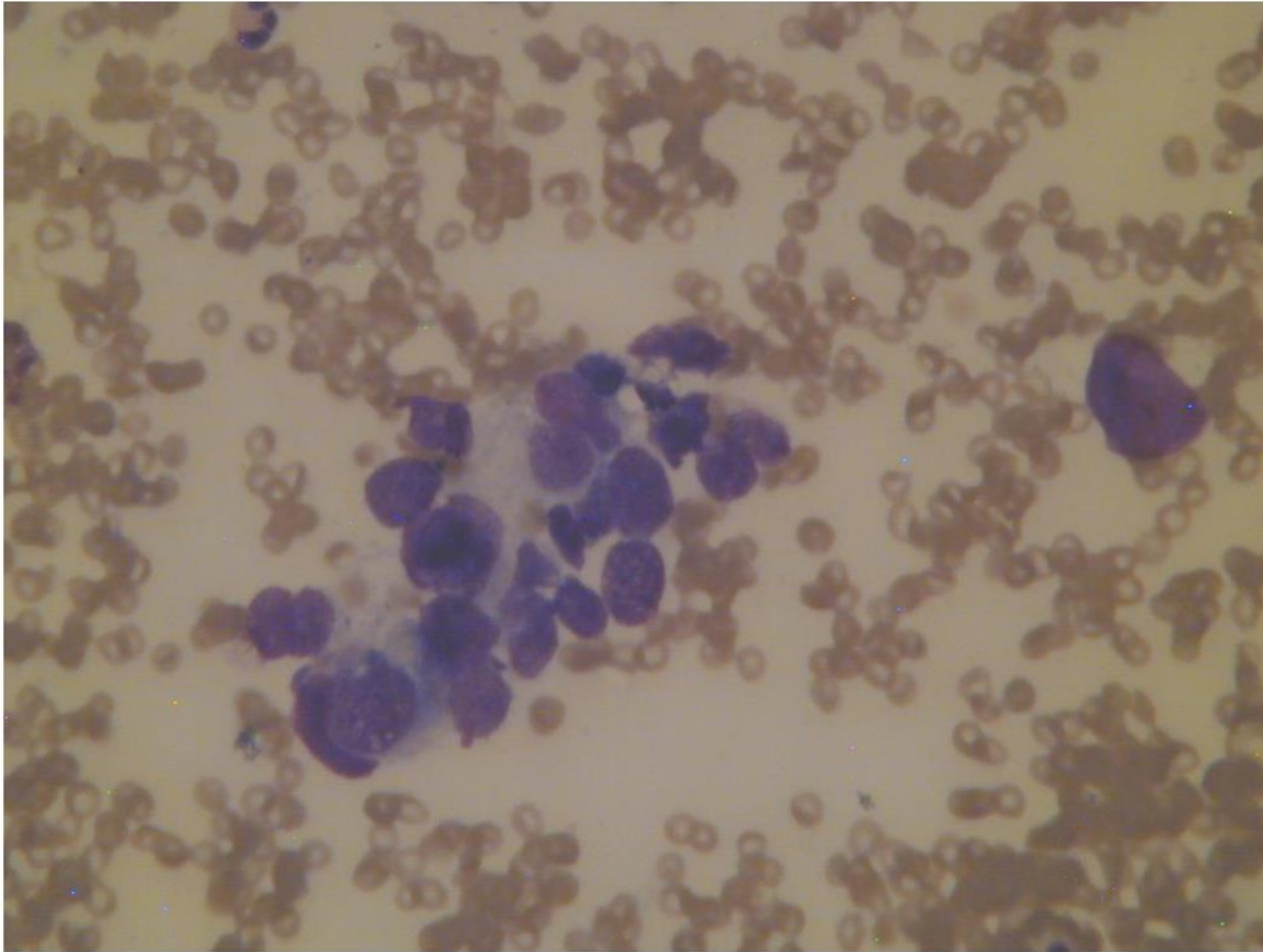
Moderately Cellular Sample with singly dispersed and loosely cohesive epithelial cells
Cells are pleomorphic and hyperchromatic

Metastatic High Grade Carcinoma

SLIDE 1 CN-344



SLIDE 2 CN-344



CASE 3 MN17-532

Young man with intermittent fever,
night sweats and weight loss.

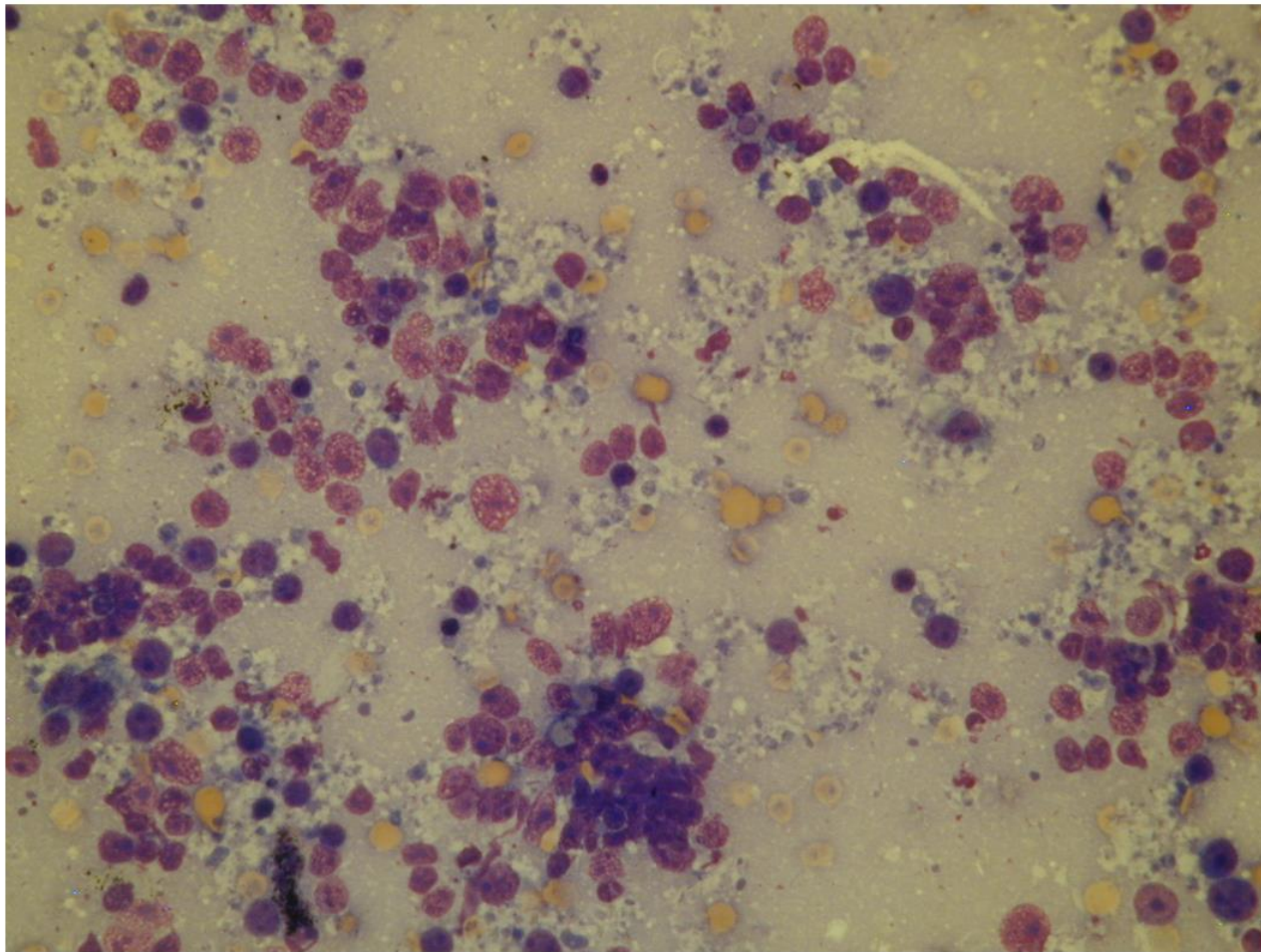
Rapid stain is highly cellular population

Cells are large with scant cytoplasm.

Nuclei contain coarse chromatin with
prominent nucleoli

-High Grade Non Hodgkin Lymphoma

SLIDE 1 MN17 532



CASE 4 MN17-2024

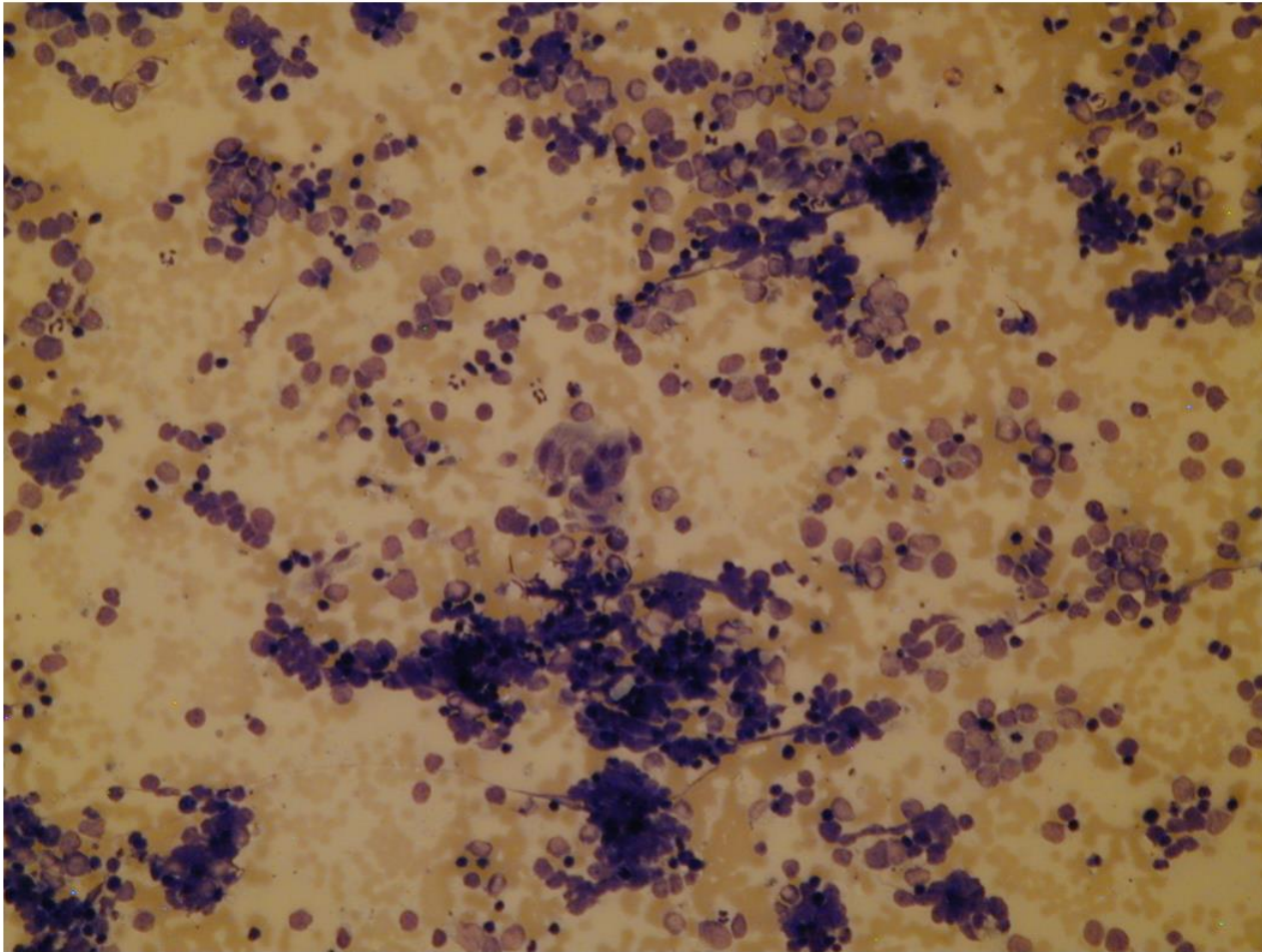
Atypical cells in small groups. Cells have small amount of cytoplasm.

Nuclear chromatin is finely dispersed with inconspicuous nucleoli

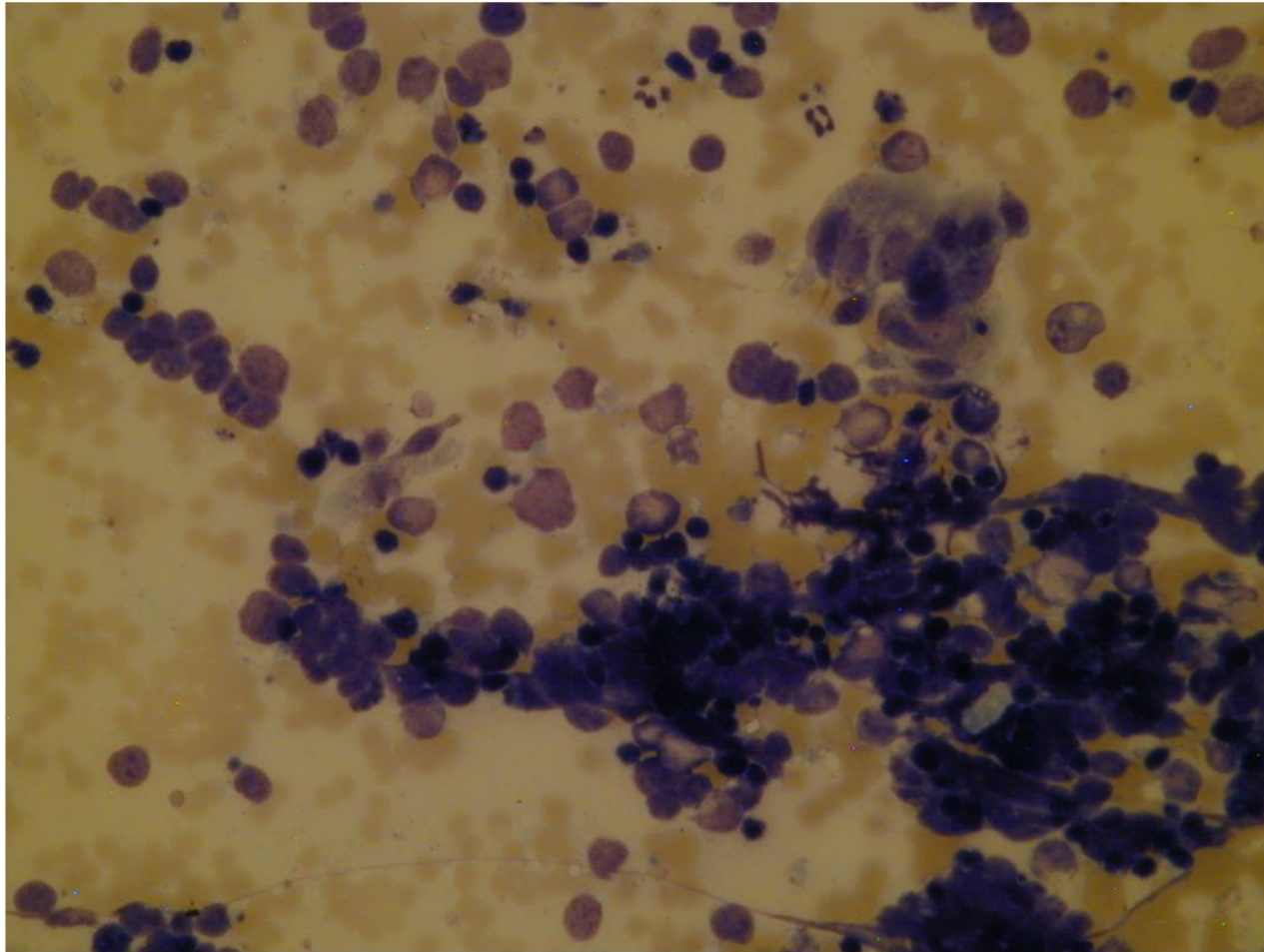
NUCLEAR MOULDING IS SEEN

METASTATIC SMALL CELL CARCINOMA

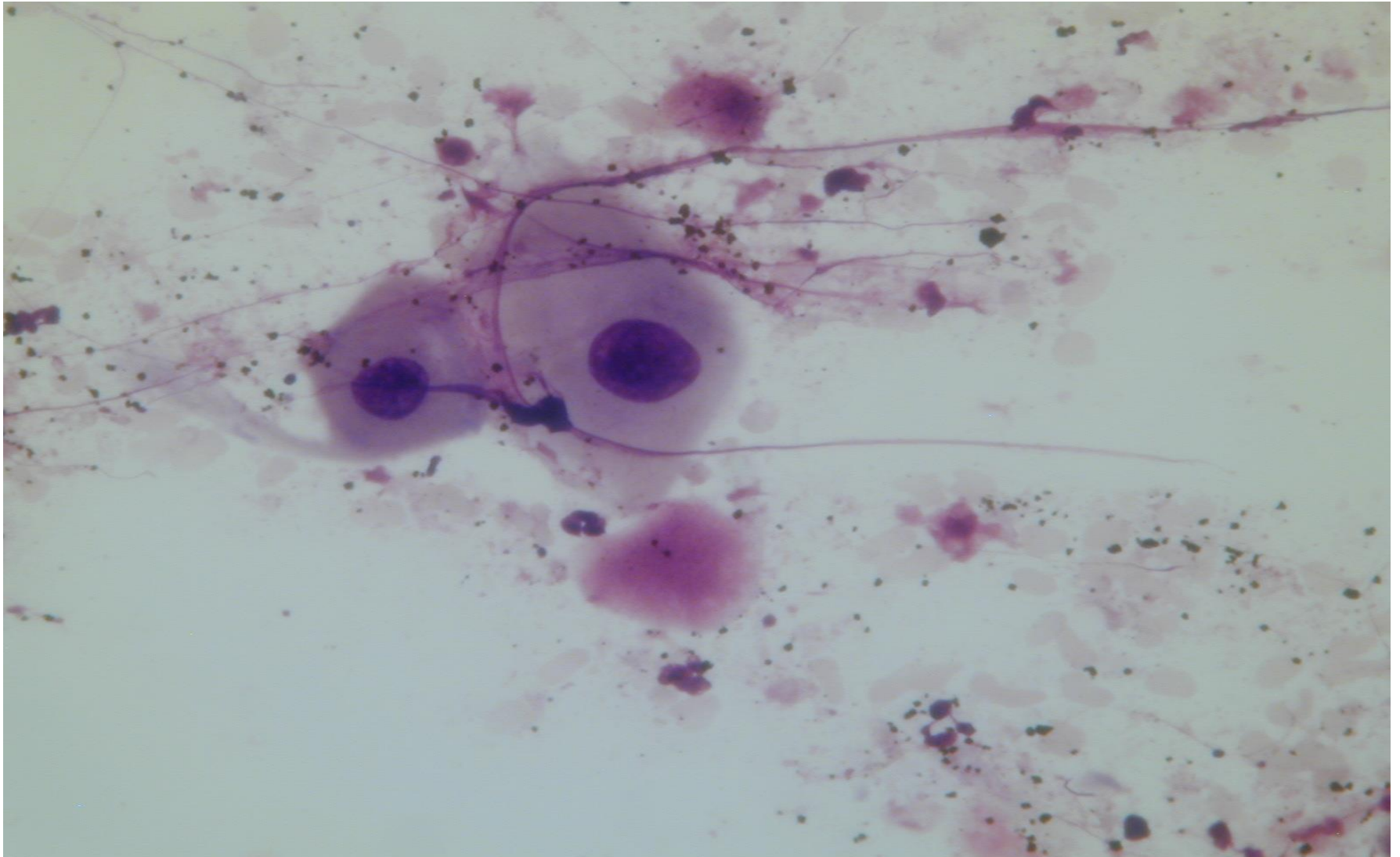
SLIDE 4 MN17 2024



SLIDE 4 MN17 2024



CASE 5 HN555
Squamous Cell Carcinoma



Case 6 MN17-939

Crowded Groups of atypical cells

Pleomorphic nuclei with coarse chromatin, small nucleoli

Acinar formation in some groups

Metastatic carcinoma- favouring adenocarcinoma

Case 7 MN17-2207

-Evidence of LN sampling in first pass and no atypical cells

Small and Large lymph node population present some that are reactive.

Second pass has clusters of cells with prominent nucleoli, vacuolated cytoplasm and some have signet cell appearance

Metastatic breast cancer as Oestrogen Receptor Positive

CASE 8 MN17-900

-Cohesive groups of atypical cells,
nuclear overlapping with enlarged
nucleus with prominent nucleoli
Focal Necrosis is present

METASTATIC ADENOCARCINOMA

CASE 9 MN17-1251

Population of small singly dispersed atypical cells with minimal cytoplasm.

Inconspicuous nucleoli, fine chromatin and nuclear moulding

SMALL CELL CARCINOMA

CASE 10 MN17-2026

- Polymorphous population of lymphoid cells with antrhocotic histiocytes suggesting sinus histiocytes and not granuloma

REACTIVE LYMPH NODE

CASE 11 MN14-1066

Astroid bodies seen and no necrosis.

Numerous epithelioid granulomas with
no necrosis

SARCOIDOSIS

CASE 12 MN17-1062

Atypical cells in small groups and predominantly single cells.

High nucleocytoplasmic ratio and moderate amount of vacuolated cytoplasm

Nuclear chromatin is vesicular with small nucleoli

METASTATIC non SMALL CELL CARCINOMA-
favouring ADENOCARCINOMA